

Unilateral or Localized Reinke's Edema (Pseudocyst) as a Manifestation of Vocal Fold Paresis: The Paresis Podule

James A. Koufman, MD, FACS; Peter C. Belafsky, MD, PhD

Background: The nosology of free-edge vocal fold lesions remains imprecise. In particular, the lesion termed *pseudocyst* remains enigmatic, because its histology is poorly defined and because its etiology is unknown. We define pseudocyst as a discrete, unilateral, localized area of Reinke's edema (without a capsule), usually occurring at the midportion of the free-edge striking zone. **Objective:** To report the demographic and clinical findings, as well as discuss our diagnostic and therapeutic strategies, in patients with unilateral Reinke's edema or pseudocyst. **Methodology:** All patients diagnosed with unilateral Reinke's edema or pseudocyst over a 2-year period (1998–1999) were identified from the clinical database of the Center for Voice Disorders of Wake Forest University, Winston-Salem, North Carolina. The record of each patient was retrospectively reviewed. **Results:** Thirteen patients were identified, 12 of whom were female. The mean age was 36 years. Sixty-nine percent (9 of 13) had unilateral pseudocyst and 31% (4 of 13) had unilateral Reinke's edema. All patients had documented vocal fold paresis on laryngeal electromyography. The 9 patients with pseudocyst underwent excision of their lesions; 7 had bilateral medialization laryngoplasties, 1 had lipoinjection, and 3 did not have surgical intervention. Significant improvement was noted postoperatively on a self-administered glottal insufficiency (symptom) index ($P < .001$). **Conclusion:** Unilateral Reinke's edema and localized Reinke's edema (pseudocyst) are distinct clinical entities, occurring most frequently in women in their fourth decade. The finding of unilateral Reinke's edema or pseudocyst should alert the clinician to the likelihood of vocal cord paresis. Surgical intervention with medialization laryngoplasty appears to be beneficial. **Key Words:** Reinke's edema, polypoid degeneration, pseudocyst, vocal fold paresis, laryngoplasty,

thyroplasty, voice disorder, hoarseness, dysphonia, laryngeal electromyography.

Laryngoscope, 111:576–580, 2001

INTRODUCTION

The nosology of free-edge vocal fold lesions is confusing and imprecise. The terms *nodule*, *prenodule*, *cyst*, *pseudocyst*, and *polyp* are not consistently and clearly defined. Consequently, heterogeneous lesions are sometimes reported as if they represent discreet clinical findings. This lack of specificity is compounded by the fact that the underlying etiological factor or factors for many of these lesions is (are) multifactorial or unknown.

Unilateral or localized Reinke's edema, having the appearance of a pseudocyst, is a relatively common finding in laryngologic practice (see Fig. 1A). At the time of surgical removal, it is obvious that these pseudocysts have no capsule (i.e., no epithelial lining; see Fig. 1B). In addition, they never involve the deeper layers of the lamina propria. Pseudocysts usually are found in young, non-smoking adult female patients.

Vocal fold paresis (VFP) is relatively common and often overlooked because it may be difficult to diagnose based on the laryngeal examination alone.^{1–4} Patients with VCP usually present with glottal closure symptoms such as breathy dysphonia, vocal fatigue, diplophonia, and odynophonia. The etiology of the VFP may be idiopathic, postviral, traumatic, neoplastic, or iatrogenic.⁴

The purpose of this article is to report our experience with the finding of unilateral Reinke's edema or pseudocyst as a manifestation of unilateral or bilateral VFP. We reviewed 13 cases seen at the Center for Voice Disorders of Wake Forest University over a 2-year period. Specifically discussed are the symptoms, findings, laryngeal electromyographic data, management strategies, and treatment outcomes.

MATERIALS AND METHODS

All patients seen at the Center for Voice Disorders of Wake Forest University over the 2-year period January 1, 1998, to December 30, 1999, with unilateral Reinke's edema or pseudocyst were identified from a clinical database. The record of each patient was retrospectively reviewed.

Presented at the Southern Section Meeting of the Triological Society in Marco Island, FL, January 2001.

From the Center for Voice Disorders of Wake Forest University, Winston-Salem, North Carolina.

Editor's Note: This Manuscript was accepted for publication January 23, 2001.

Send Correspondence to James A. Koufman, MD, Center for Voice Disorders, Department of Otolaryngology, Wake Forest University School of Medicine, Medical Center Boulevard, Winston-Salem, NC, U.S.A. Website: www.wfubmc.edu/voice

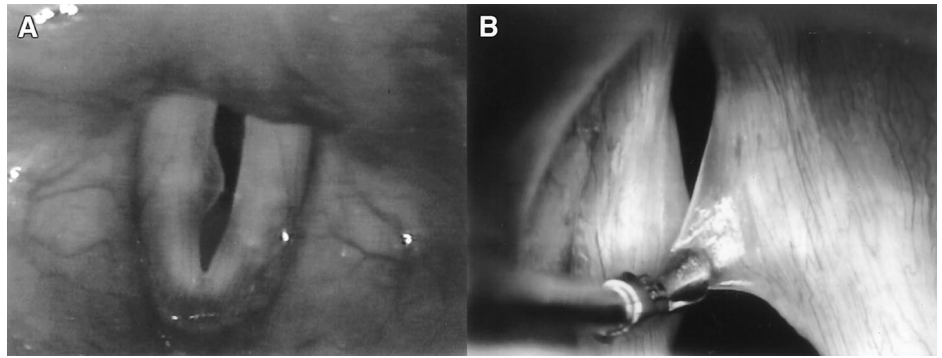


Fig. 1. Example of unilateral paresis-related pseudocyst (so-called "paresis podule"). (A) Appearance of the lesion on transnasal fiberoptic (indirect) laryngoscopy. (B) Intraoperative appearance of the lesion at direct laryngoscopy. Note that the lesion has no epithelial lining, i.e., no capsule.

Each patient underwent transnasal fiberoptic laryngoscopy (TFL) with videostroboscopy, acoustical analysis with electroglottography, and laryngeal electromyography (LEMG). Our technique of LEMG has been previously reported.⁵⁻⁷ We routinely test the thyroarytenoid and cricothyroid muscles supplied by the recurrent and superior laryngeal nerves. Both sides are tested and recruitment, waveform morphology, and the presence or absence of spontaneous activity is evaluated. Recruitment is defined as the orderly activation of new motor units with increased muscle contraction. In LEMG, recruitment is assessed during activation of the vocal folds (phonation). Figure 2 shows two LEMG tracings, one showing normal (full) recruitment and the other showing reduced recruitment. Reduced motor unit recruitment is the *sine qua non* of VFP. Waveform morphology and the presence of spontaneous activity are used to assess the age of the injury, potential for recovery, and existence of ongoing degeneration. Further discussion of these parameters does not directly relate to the presence/absence of VFP and is beyond the scope of this paper.⁵⁻⁷

A subjective self-administered glottal insufficiency questionnaire (the Glottal Closure Index) was obtained from every patient prior to being examined. This survey asks about symptoms of vocal fatigue, effortful phonation, odynophonia, and breathy dysphonia on a 5-point scale (Table I).

During the course of transnasal fiberoptic laryngoscopy, each patient was asked to perform the */i/-sniff* maneuver to evaluate vocal fold mobility. The */i/* adducts and the *sniff* maximally abducts the vocal folds. Stroboscopy was performed at several pitches to evaluate differences in vocal fold tone. Increased amplitude unilaterally suggests decreased tone, particularly in the mid-frequencies. In addition to TFL, patients underwent videostroboscopy with an optical telescope to provide magnification. All lesions were photographed.

All persons who failed conservative management were offered excision, medialization laryngoplasty, and/or injection augmentation. For those who underwent surgery, pre- and postoperative Glottal Closure Index scores were evaluated using a paired-samples *t* test.

RESULTS

Thirteen patients with unilateral Reinke's edema or pseudocyst of the vocal fold were identified. Figure 3 displays 12 of the lesions. Twelve of the patients were female. The mean age was 35.6 years (range, 18-46 y). Sixty-nine percent (9 of 13) had unilateral pseudocysts and 31% (4 of 13) had unilateral Reinke's edema. Only three of the

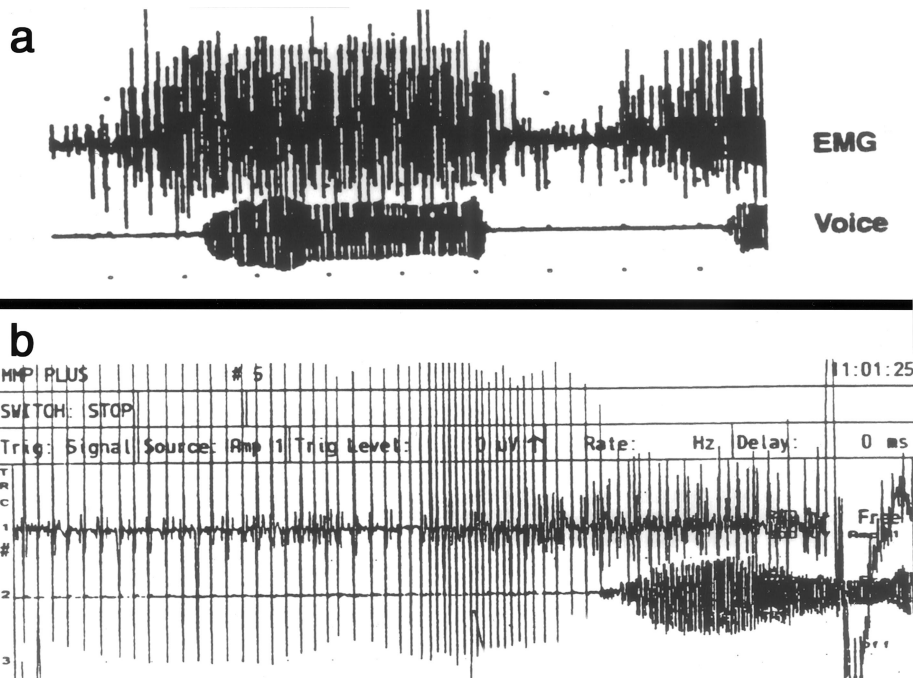


Fig. 2. Recruitment of motor unit potentials during laryngeal EMG. (A) This recording shows normal recruitment of motor unit potentials in a thyroarytenoid muscle during phonation. (B) This tracing shows reduced recruitment in a thyroarytenoid muscle during phonation.

TABLE I.
The Glottal Closure Index.
Circle the appropriate response

Within the last MONTH, how did the following problems affect you?	0 = No problem 5 = Severe Problem					
Speaking took extra effort	0	1	2	3	4	5
Throat discomfort or pain after using your voice	0	1	2	3	4	5
Vocal fatigue (voice weakened as you talked)	0	1	2	3	4	5
Voice cracks or sounds different	0	1	2	3	4	5

patients were smokers. Table II displays the clinical and demographic data on all 13 patients.

The etiologies of the VCP were idiopathic 46% (6 of 13), postviral neuropathy 31% (4 of 13), and iatrogenic 23% (3 of 13). Of the iatrogenic group, one patient had undergone previous tonsillectomy, one had had thyroid surgery, and one had had a hysterectomy. All three had had general endotracheal intubation.

All patients had evidence of vocal fold paresis on LEMG. Twenty-three percent (3 of 13) of the patients had findings of unilateral neuropathy and 77% (10 of 13) had findings of bilateral paresis. As of this writing, 77% (10 of 13) of the patients in this series have undergone voice rehabilitation surgery. All 9 patients with pseudocyst underwent excision; 7 have had bilateral medialization laryngoplasties, 2 have had a lipoinjection, and 3 have not required surgical intervention. Of the 10 patients who elected surgical intervention, the Glottal Closure Index decreased from a mean of 14.4 (\pm 2.9 standard deviation [SD]) to a mean of 4.7 (\pm 5.1 SD). This decrease is highly significant ($P < .001$).

DISCUSSION

Unilateral Reinke's edema and localized Reinke's edema (pseudocyst) are distinct clinical entities, which are

relatively common in laryngology practice. Most commonly, such lesions occur in non-smoking women in their fourth decade, and they appear to be universally associated with vocal fold paresis.

Patients usually present with glottal closure symptoms: breathiness, effortful phonation, vocal fatigue, voice breaks, and odynophonia. On initial examination, hyperkinetic laryngeal biomechanics are observed, so that the clinician may falsely presume that the lesion is secondary to a (functional) muscle tension dysphonia. After the compensatory vocal behaviors are unloaded (temporarily removed with voice therapy techniques), these patients may acoustically decompensate, i.e., the voice may become worse by acoustical parameters. Thus, it appears that these lesions may be the consequence of vocal fold paresis and not the primary cause of the problem. Laryngeal electromyography is required to confirm the diagnosis of VFP.

The relatively high incidence of pseudocyst formation in females (compared with males) is comparable to the incidence (ratio) of vocal nodules in adult female and male patients. Hormone receptors are known to exist in the nucleus and cytoplasm of cells in the vocal fold.^{8,9} Estrogens and progesterones have also been implicated in laryngeal edema.¹⁰ Although it is possible that the female

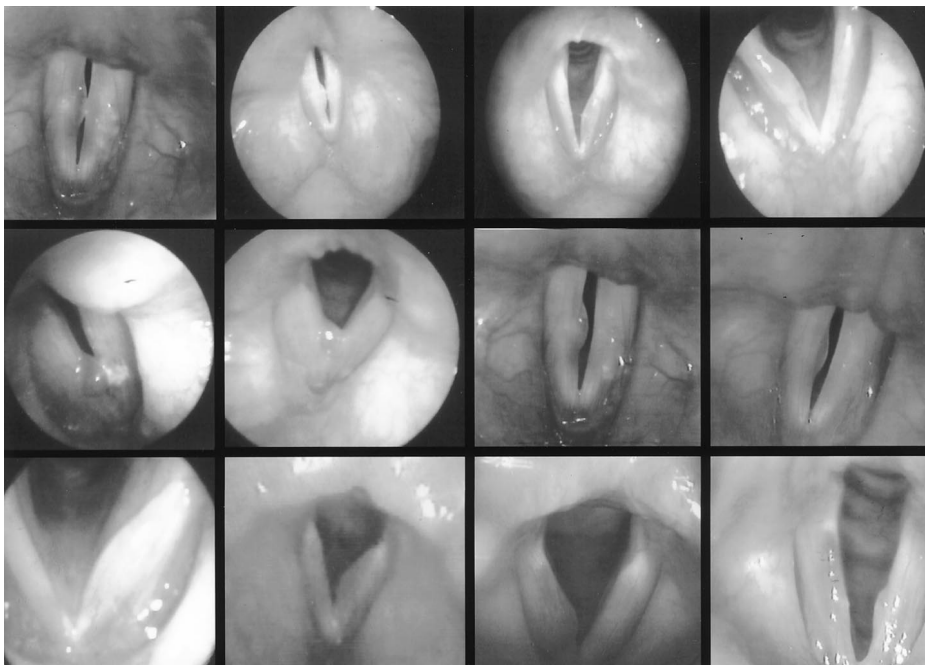


Fig. 3. Fiberoptic appearance of the lesions of 12 of the reported patients. Three had unilateral, fusiform Reinke's edema, and nine had unilateral paresis nodules (pseudocysts).

TABLE II.
Patient Data.

Patient No.	Age (y)/ Sex	Lesion	Right CT	Left CT	Right TA	Left TA	Treatment	Etiology of Paresis
1	43/F	Left PP	+				Excision lipoinjection	Idiopathic
2	35/F	Left PP	+		+	+	Staged excision BML	PVWN
3	32/F	Right PP		+	+	+	Staged excision BML	Idiopathic
4	41/F	Right PP		+	+	+	Staged excision BML	Idiopathic
5	46/F	Left PP		+	+	+	Staged excision BML	Idiopathic
6	37/F	Left PP			+	+	Staged excision BML	PVWN
7	28/F	Left RE		+		+		PVWN
8	35/F	Left RE		+		+	Excision	Idiopathic
9	18/F	Right PP	+	+	+	+	Staged excision BML	PVWN
10	43/F	Right RE	+	+	+	+	BML	latrogenic
11	40/F	Right RE	+	+		+		latrogenic
12	29/F	Left PP		+	+	+		latrogenic
13	30/M	Right PP	+	+		+	Excision	Idiopathic

PP = paresis podule; RE = Reinke's edema; CT = cricothyroid muscle; TA = thyroarytenoid muscle; BML = bilateral medialization laryngoplasty; PVWN = post-viral vagal neuropathy; + = reduced (abnormal) recruitment on laryngeal EMG.

preponderance of these pseudocysts is hormonally related, gender differences in aerodynamic properties and epithelial susceptibility to inflammatory disease and trauma cannot be excluded. In other words, pseudocysts, like classical vocal nodules, are more common in females than males, and the difference in incidence may be multifactorial, related to hormonal, anatomic, inflammatory, and aerodynamic factors.

We have chosen the name **paresis podule** to describe the paresis-related pseudocyst. We coin the term *podule* from the word *pod*, meaning *anatomical pouch or seedcase*. The term *pod* is derived from the 15th century English word *codpiece*, which refers to a flap obscuring the opening in front of men's britches.⁸ Paresis podules resemble a pod or codpiece. Like vocal nodules, these lesions appear on the midportion of the free-edge striking zone as a consequence of effortful glottal closure, but they are sessile and lack a capsule. Thus, the term *podule* is derived from its pod-like appearance and its nodule-like location. By comparison, a laryngeal polyp is a projecting or pedunculated mass of hypertrophied mucosa, usually with a stalk.

Paresis podules are presumably a traumatic consequence of effortful glottal closure. In some ways they appear to be similar to blisters of the skin that result from sheering trauma. However, how and why do they occur unilaterally; and why do all patients with VCP not develop such lesions?

Under normal physiological circumstances, approximation of the vocal folds during non-effortful phonation is achieved primarily by the interarytenoideus muscle.¹¹ As subglottal pressure builds, the vocal folds separate. Then, as air flow continues through the relatively narrow glottis, the resulting negative pressure and myoelastic properties of the tissues result in closure (Bernoulli's effect), thus completing the glottal cycle.

In VCP, glottal closure is the result of asymmetrical muscular forces. Glottal closure is effortful and other in-

trinsic as well as extrinsic laryngeal muscles are recruited to help achieve closure. Because of forced closure, higher subglottal pressures are generated, and normal epithelial shearing forces are also increased. In their paper on vocal fold ectasias and varices, Hochman et al. describe the region of maximal shearing force within the superficial layer of the lamina propria as the striking zone, and they postulate that these shearing forces lead to microvasculature damage.¹² In the case of the paresis podule, we theorize that asymmetrical, effortful closure in the region of the striking zone resulting from the underlying VFP is initially responsible for the development of the lesion. Once a podule begins to develop (on one side), the shearing forces created by subglottal pressure may become increasingly asymmetrically distributed. This is because the injured (podule) side has increased mass and increased compliance. Within the striking zone, the podule may then effectively bear the brunt of increased subglottal pressure, somewhat improve glottal closure, and thus, protect the contralateral vocal fold from similar injury.

Clinically, we have observed that in some cases podules recur after surgical removal and in other cases they do not. Furthermore, the majority of patients with VCP never develop paresis podules. We postulate that podule development may depend on several factors, including: 1) asymmetrical muscular activity; 2) glottal incompetence; 3) mucosal fragility; 4) hormonal influences; 5) vocal misuse/abuse; and/or 6) concomitant inflammatory disease. Bilateral Reinke's edema, for example, appears to be a consequence of longstanding inflammation (reflux and/or tobacco). It may be that several cofactors need to be present before a podule develops. The question is similar to the question of why some patients with muscle tension dysphonias develop vocal nodules, whereas others do not.

In our series, patients who failed conservative management were offered surgical excision, medialization laryngoplasty, and/or lipoinjection. Three patients underwent pseudocyst excision as first line therapy (patient nos.

3, 6, and 13). Two of these three (patient nos. 3 and 6) experienced a recurrence and had a simultaneous excision and laryngoplasty as definitive treatment. Patient no. 13 has not had a recurrence and remains asymptomatic 2 years postoperatively. One patient underwent a simultaneous excision and lipoinjection (patient no. 1) and 3 patients underwent simultaneous excision and laryngoplasty as initial treatment (patient nos. 2, 4, and 5).

Patient improvement after laryngoplasty and/or lipoinjection was demonstrated in these patients by a decrease in the glottal closure index from a preoperative mean of 14 to a postoperative mean of 5 ($P < .001$). None of these lesions have recurred (mean follow-up, 17.5 mo). Three patients have not had surgical intervention and remain relatively symptomatic (mean glottal closure index of 13).

Case Example

A 32-year-old woman presented to the Center for Voice Disorders at Wake Forest University in May 1998 with a chief complaint of severe breathy dysphonia. Transnasal fiberoptic laryngoscopy and videostroboscopy at that time revealed a unilateral pseudocyst on the right true vocal fold in the region of the striking zone. In July 1998, after failure of voice therapy, she underwent excision of the pseudocyst. She initially did well and her Glottal Closure Index improved from a preoperative value of 8 to a postoperative value of 1.

In October 1998, however, she returned to the clinic with recurrent glottal closure symptoms (Glottal Closure Index increased to 7) and was seen to be developing a recurrence of the pseudocyst. Comprehensive evaluation in the voice laboratory was obtained. On electroglottography, the mean glottal contact percentage was 32%, which decreased to 25% when the patient was unloaded (normal 40%–45%). Vocal fold paresis was suspected and LEMG confirmed “old” bilateral paresis of the thyroarytenoid muscles. The patient underwent bilateral medialization laryngoplasty in December 1998. As of this writing, she is almost 2 years postoperative with no vocal symptoms (Glottal Closure Index of 0), a normal voice (by all voice laboratory criteria), and with no evidence of recurrent pseudocyst.

CONCLUSION

- 1) Unilateral (fusiform) Reinke’s edema and localized Reinke’s edema (pseudocyst) form a distinct

clinical entity, typically occurring in relatively young, non-smoking women.

- 2) We term these pseudocysts **paresis podules** because they are uniformly associated with VFP, and because they are pod-like in appearance and nodule-like in location.
- 3) The presence of unilateral Reinke’s edema or pseudocyst should alert the clinician to an underlying VFP. Voice therapy is used to remove compensatory vocal behavior, and laryngeal EMG is necessary to confirm the diagnosis.
- 4) Surgical intervention with medialization laryngoplasty and/or lipoinjection appears to be successful for patients who fail conservative (voice therapy) management.

BIBLIOGRAPHY

1. Adour KK, Schneider GD, Hilsinger L. Acute superior laryngeal nerve palsy: analysis of 78 cases. *Otolaryngol Head Neck Surg* 1980;88:418–424.
2. Dursum G, Sataloff RT, Spiegel JR, Mandel S, Heuer RJ, Rosen DC. Superior laryngeal nerve paresis and paralysis. *J Voice* 1996;10:206–211.
3. Dray TG, Robinson LR, Hillel AD. Idiopathic bilateral vocal fold weakness. *Laryngoscope* 1999;109:995–1002.
4. Koufman JA, Postma GN, Cummins MM, Blalock PD. Vocal fold paresis. *Otolaryngol Head Neck Surg* 2000;122:537–541.
5. Koufman JA, Walker FO, Joharji GM. The cricothyroid muscle does not influence vocal fold position in laryngeal paralysis. *Laryngoscope* 1995;105:368–372.
6. Koufman JA, Walker FO. Laryngeal electromyography in clinical practice: indications, techniques, and interpretation. *Phonoscope* 1998;1:57–70.
7. Postma GN, Koufman JA. Laryngeal electromyography. *Curr Opin Otolaryngol* 1998;6:411–415.
8. Newman SR, Butler J, Hammond EH, Gray SD. Preliminary report on hormone receptors in the human vocal fold. *J Voice* 2000;14:72–81.
9. Narbaitz R, Stumpf WE, Sar M. Estrogen target cells in the larynx: autoradiographic studies with 3H-diethylstilbestrol in fetal mice. *Horm Res* 1980;12:113–117.
10. Abitbol J, Abitbol P, Abitbol B. Sex hormones and the female voice. *J Voice* 1999;13:424–424.
11. Hillel AD. The study of laryngeal muscle activity in normal human subjects and in patients with laryngeal dystonia using multiple fine wire electromyography. *Laryngoscope* (submitted for publication).
12. Hochman I, Hillman R, Sataloff R, Zeitels S. Ectasias and varices of the vocal fold: clearing the striking zone. *Ann Otol Rhinol Laryngol* 1999;108:10–16.